CASE REPORT

Radiolucency of anterior mandible crossing midline

Narendra Prakash Rai[1], Anshul Srivastava[2], Anshumali Srivastava[3], Abhinav Sharma[4]

[1]Department of Oral Medicine and Radiology, Faculty of Dentistry, Lincoln University College, Petaling Jaya, Selangor, Malaysia, [2]Department of Orthodontics, Rama Dental College, Kanpur, Uttar Pradesh, India, [3]Department of Oral Medicine & Radiology, Awadh Dental College & Hospital, Jamshedhpur, Jharkhand, India, [4]Private Practitioner, Gurgaon, Haryana, India

Correspondence
Anshul Srivastava, Department of Orthodontics, Rama Dental College, Kanpur, Uttar Pradesh, India.
Email: dranshulortho@gmail.com

Received 21 August 2015;
Accepted 12 October 2015

doi: 10.15713/ins.ijmdcr.31

How to cite the article:
Rai NP, Srivastava A, Srivastava A, Sharma A. Radiolucency of anterior mandible crossing midline. Int J Med Dent Case Rep 2015;1:1-3.

Abstract

Odontogenic cysts are the most commonly occurring cysts in the jaws and are the reason for the radiolucent appearances. The radicular cyst is a type of an inflammatory cyst, caused due to pulpal necrosis followed by trauma or caries, with an associated inflammatory response at the periapical region. Many a times it is difficult to differentiate from other bony lesions and it poses diagnostic challenges due to its location. Here, we present a case of large radicular cyst of anterior mandibular region crossing midline which poses radiographic diagnostic challenges.

Keywords: Inflammatory cyst, mandible, radicular cyst, radiolucent

Introduction

Infections due to odontogenic etiology are the common cause for the radiolucency seen in the jaws. These can be developmental or inflammatory in origin. Most commonly occurring odontogenic etiology is an infection of the tooth due to microbial aggregation, dental caries, trauma, or any insult to the tooth which causes death and necrosis of the pulp which leads to periapical changes and radiolucent appearance in the jaws. Radicular cysts are the most common jaw cyst seen due to periapical infection, and it accounts for almost 60% of all the jaw cysts.[1] Several studies have been done correlating the size of the radiolucency and histopathologically findings between cysts and granuloma.[2] Studies suggest that approximately 44% of all the apical lesions are inflammatory periapical cysts.[3] These can be seen in the entire tooth bearing areas, most commonly being seen in the maxilla compared to the mandible.[4,5] Here, we present a long standing case of infected radicular cyst causing extraoral sinus discharge and large unilocular radiolucency crossing midline with the radiographic differential diagnosis.

Case Report

A 21-year-old male patient visited the department of oral medicine and radiology, KVG dental college and hospital, Sullia with complain of discharge from lower chin region since 1 month. It was associated with pain which was dull and intermittent in nature. The patient also gave a history of fall at the age of 8 years with a fracture of lower front teeth. 4 years back patient noticed swelling in the lower chin region which was firm and non-fluctuant in nature with draining sinus, it was insidious in onset and not associated with pain, the patient visited a doctor for the same and took medicines, but it was not relieved. On inspection draining sinus noticed in the submental region 2 cm below the lower border of mandible [Figure 1]. Area around sinus was erythematous. On palpation, pus discharge, tenderness, local rise in temperature was felt. Intraorally obliteration of labial vestibule in relation to 31, 41 associated with discoloration of the tooth was noticed. Grade I mobility was also present in relation to 31, 41, 42 with a fracture of the coronal third. Electric pulp testing showed no response in relation to 31, 41 and delayed response in relation to 32, 42. A provisional diagnosis of chronic periapical abscess in relation to 31, 41 with extraoral sinus discharge was given. Differential diagnosis of phoenix abscess, infected granuloma and osteomyelitis were considered. The Intraoral periapical radiograph showed fractured 31, 41, 42 with an ill-defined hazy radiolucency at the periapex with the loss of lamina dura [Figure 2]. A panoramic radiograph revealed a well-defined solitary unilocular homogeneous radiolucency of size 10 cm × 3.5 cm extending from mesial of 43 until the distal root of 33 having a corticated border with well-defined margins, pushing the root apices of 33 and 43 [Figure 3]. Incisional biopsy was performed to confirm the diagnosis which showed predominantly connective tissue consisting of mature collagen fibers with fibroblasts and few areas of granulation tissues.

Granulation tissue consists of collagen fibers, densely infiltrated with chronic inflammatory cells and few blood capillaries. Lumen lined by the stratified squamous epithelium of 3-6 cell layers [Figure 4] which was suggestive of the infected radicular cyst. Area was opened surgically, and the lesion was enucleated in toto with removal of complete epithelial cystic lining without recurrence after a follow-up of 1 year (Figure 5).

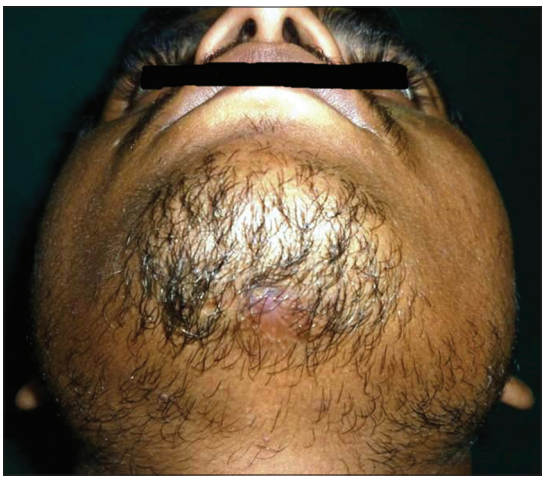

Figure 1: Extraoral submental draining sinus

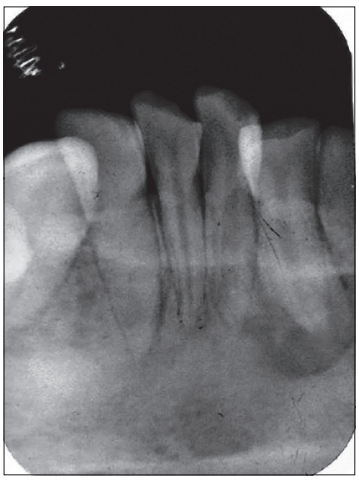

Figure 2: Intraoral periapical radiograph of 31, 41, 42

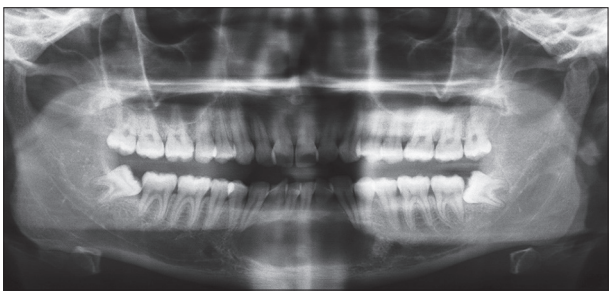

Figure 3: Panoramic radiograph of patient

Discussion

Cysts and tumors are commonly occurring pathological condition in both the jaws, most frequently due to odontogenic reasons. The radicular cyst is an inflammatory jaw cyst arising from epithelial remnants of the periodontal ligament as a result of infection and inflammation which is generally seen due to pulpal necrosis. The radicular cyst is classified as an inflammatory cyst and commonly seen in the apical region of the permanent tooth and rarely associated with the apex of deciduous dentition.[6] Bacteria can also reach until the apical area through gingival sulcus and periodontal pockets and cause infections. Two theories are postulated regarding the formation of cyst cavity. The nutritional deficiency theory is based on the fact that the cells present in the center are devoid of nutrition and undergo liquefaction necrosis and degeneration which slowly converts to the necrotic area. According to the abscess, theory is proliferating surrounding epithelium lines the abscess cavity formed due to lysis and necrosis.[7,8] In the last phase, cyst grows in size due to osmosis. Thickness of

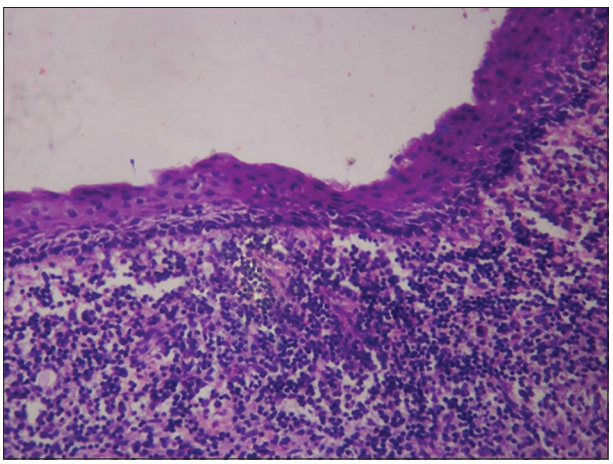

Figure 4: Histopathological view of lesion (H and E, ×10)

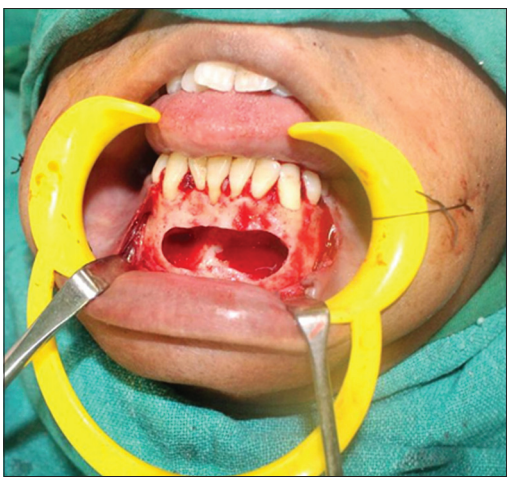

Figure 5: Surgical excision of lesion

the epithelium lining will be 6-20 layers but may go higher in severe infectious and inflammatory conditions depending on the case. The epithelium line will be lined by non-keratinized stratified squamous epithelium. Ortho or parakeratinization is seen in approximately 2-3% of the cases.[9] Studies show radicular cyst is more common in 3rd-5th decades of life, more commonly seen among males and in maxilla as compared to the mandible and is rarely seen in deciduous dentition 0.5-3.3%.[10,11] Clinically, the associated tooth will be non-vital, discolored, and asymptomatic until it's infected secondarily and are diagnosed radiographically. Resorption of the root is an uncommon finding.

Our case presented with discolored mandibular anterior teeth with extraoral sinus discharge in the lower chin region with a radiographic finding of big unilocular radiolucency in the apical region crossing midline. Other differential diagnoses were ruled out on the basis of history, clinical and radiographic presentation and histopathological examination. The present case is consistent with the literature; apart from its location is mandibular anterior region.

Radicular cyst, granuloma, periodontal cyst, early stage periapical cemental dysplasia, central giant cell granuloma, and the keratocystic odontogenic tumor can also be considered as a radiographic differential diagnosis. Various treatment options can be followed like root canal treatment, extraction of tooth and marsupialization/enucleation depending on the clinical presentation of the lesion. Recurrence of the lesion has also been seen in cases where cystic lining was not removed completely.

Multiple radicular cysts can be seen in dentinogenesis imperfect and dense in dente. According to the literature review, descriptions of squamous cell carcinoma originating from the epithelial lining of long standing radicular cysts also been seen.[9]

Conclusion

Radicular cyst a common lesion seen in the jaw bones, chronic cases may lead to extraoral sinus discharge. Early stage lesion may go unnoticed, so careful clinical examination is required supported by radiographs. Radiographically, it may pose diagnostic dilemmas due to its location, each entity should be ruled out carefully on the basis of history, clinical, and histopathological examination.

References

1. Joshi UK, Patil SK, Siddiqua A. Nasopalatine cyst a rare entity. Int J Dent Clin 2010;2:34-6.
2. Stockdale CR, Chandler NP. The nature of the periapical lesion – A review of 1108 cases. J Dent 1988;16:123-9.
3. Bhaskar SN. Nonsurgical resolution of radicular cysts. Oral Surg Oral Med Oral Pathol 1972;34:458-68.
4. Nair PN. New perspectives on radicular cysts: Do they heal? Int Endod J 1998;31:155-60.
5. Rees JS. Conservative management of a large maxillary cyst. Int Endod J 1997;30:64-7.
6. Grewal HK, Batra R. Non syndromic bilateral dentigerous cysts - A case report. Int J Dent Clin 2010;2:49-51.
7. Latoo S, Shah AA, Jan SM, Qadir S, Ahmed I, Purra AR, *et al.* Radicular cyst. JK Sci 2009;11:187-9.
8. Huang GT. Apical cyst theory: A missing link. Dent Hypotheses 2010;1:76-84.
9. Shear M, Speight P. Cysts of Oral and Maxillofacial Regions. 4th ed. Oxford: Blackwell; 2007. p. 123-42.
10. Joshi NS, Sujan SG, Rachappa MM. An unusual case report of bilateral mandibular radicular cysts. Contemp Clin Dent 2011;2:59-62.
11. Riachi F, Tabarani C. Effective management of large radicular cysts using surgical enucleation vs. Marsupialisation. IAJD 2010;1:44-51.